AIS PennHIP

(877) 727-6800 www.antechimagingservices.com

Owner's Copy

PennHIP Report

Referring Veterinarian: Dr Kristine Willaman	Clinic Name: South Willamette Veterinary Clinic
Email: 22willaman@gmail.com	Clinic Address: 255 Emerald Parkway Creswell, OR 97426
	Phone: (541) 895-5665
	Fax:

Patient Information

Client: Lindsay	Tattoo Num:
Patient Name: Kitty	Patient ID: 14637-632
Reg. Name: Kitty	Registration Num:
PennHIP Num: 205629	Microchip Num:
Species: Canine	Breed: MIXED BREED
Date of Birth: 15 Mar 2023	Age: 17 months
Sex: Female	Weight: 25 lbs/11.3 kgs
Date of Study: 19 Aug 2024	Date Submitted: 20 Aug 2024
Date of Report: 22 Aug 2024	

Findings

Distraction Index (DI): Right DI = 0.40, Left DI = 0.38.

Osteoarthritis (OA): **No radiographic evidence of OA for either hip.**

Cavitation/Other Findings: No cavitation present.

Interpretation

Distraction Index (DI): The laxity ranking is based on the hip with the greater laxity (larger DI). In this case the DI used is 0.40.

OA Risk Category: The DI is between 0.31 and 0.49. This patient is at mild risk for hip OA.

Distraction Index Chart:

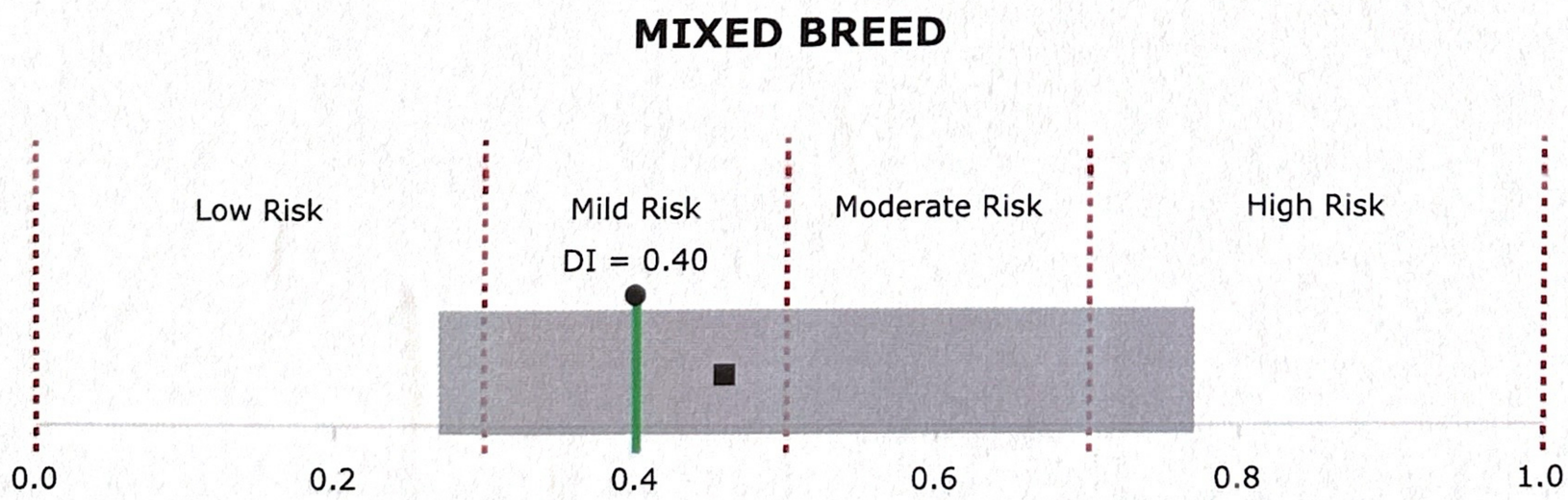

BREED STATISTICS: This interpretation is based on a cross-section of 12708 canine patients of the MIXED BREED breed in the AIS PennHIP database. The gray strip represents the central 90% range of DIs (0.27 - 0.77) for the breed. The breed average DI is 0.46 (solid square). The patient DI is the solid circle (0.40).

SUMMARY: The degree of laxity (DI = 0.40) falls within the central 90% range of DIs for the breed. This amount of hip laxity places the hip at a mild risk to develop hip OA. **No radiographic evidence of OA for either hip.**

ORTHOPEDIC FOUNDATION FOR ANIMALS, INC.

KITTY
registered name

HYBRID
breed

film/test/lab #

[redacted]
tattoo/microchip/DNA profile

2571938
application number

08/22/2024
date of report

NOREG2571938
registration no.

F
sex

03/15/2023
date of birth

17
age at evaluation in months

OFA – THE CANINE HEALTH INFORMATION CENTER – SINCE 1966

A Not-For-Profit Organization

HY-BCA6855/17F/P-VPI
O.F.A. NUMBER

This number issued with the right to correct or revoke by the Orthopedic Foundation for Animals.

RESULTS:
Normal cardiovascular examination via auscultation - No evidence of congenital or acquired heart disease was noted. Since acquired heart disease may develop later, these evaluation results remain valid for one year, and annual examinations are recommended to continue to monitor cardiac health.

NORMAL/CLEAR - PRACTITIONER

owner
LINDSAY [redacted]
EUGENE OR 97404

OFA eCert
Verify QR scan

G.G. KELLER, DVM, MS, DACVR
CHIEF OF VETERINARY SERVICES

www.ofa.org

This electronic OFA certificate was generated on: 08/22/2024

This certification can be verified on the OFA website by entering the dog's registration number into the orange search box located at the top of the page or by scanning the QR code above.

If there are any errors on this certificate, please email CORRECTIONS@OFA.ORG to request a correction.

Orthopedic Foundation for Animals, Inc.
2300 E. Nifong Blvd.
Columbia, MO 65201-3806

OFA website: www.ofa.org
E-mail address: ofa@ofa.org
Phone number: 573-442-0418
Fax number: 573-875-5073